



# MULTIDISCIPLINARY *SCIENCE JOURNAL*

VOLUME - 3



[WWW.ECOSCIENCEJOURNALS.COM](http://WWW.ECOSCIENCEJOURNALS.COM)



**ISSN** INTERNATIONAL  
STANDARD  
SERIAL  
NUMBER  
UNITED STATES  
ISSN:3067-1221; CODEN: USA

# Cerebral Arterial Variants and the Neurogenesis-Angiogenesis Axis: Implications for Intraoperative Neurophysiological Monitoring, A Narrative Review and Conceptual Synthesis

Seyedeh Haniyeh Mortazavi<sup>1\*</sup>

*1.Surgical Neurophysiologist, Neuromodulation and Pain Research Center, Shiraz University of Medical Sciences, Shiraz, Iran.*

**Article Info:** Received: 18 Jun 2026, Accepted: 01 Jul 2026, Published: 06 Jul 2026



## ABSTRACT:

The cerebral arterial tree displays substantial inter-individual anatomical variability, arising from incomplete, asymmetric, or persistent regression of embryonic vascular plexuses. Beyond their established relevance to interventional and surgical planning, these variants intersect with a second, less frequently connected body of evidence: the molecular and cellular coupling between angiogenesis and neurogenesis within the adult and injured brain. Intraoperative neurophysiological monitoring (IONM), now standard practice in cerebrovascular and skull-base surgery, provides a continuous functional readout of neural pathways whose integrity depends on both the conducting arteries and their downstream microvascular and neurogenic niches. This narrative review synthesizes current literature across three domains: (1) the embryology and clinical significance of cerebral arterial variants, (2) the coupling of neurogenesis and angiogenesis in the neurovascular niche, and (3) the application and diagnostic performance of IONM in cerebrovascular surgery. Building on this synthesis, we outline a conceptual, hypothesis-generating framework in which preoperative knowledge of a patient's vascular variant anatomy and collateral capacity could inform the interpretation of intraoperative signal changes and guide future correlative research. This article is offered as a perspective intended to motivate mechanistic and clinical investigation; it does not report new anatomical findings, original patient data, or a completed study.

**Keywords:** cerebral arterial variants, neurovascular niche, angiogenesis, neurogenesis, intraoperative neurophysiological monitoring, collateral circulation, circle of Willis.

## CORRESPONDENCE

Seyedeh Haniyeh Mortazavi

Neuromodulation and Pain Research Center, Shiraz University of Medical Sciences, Shiraz, Iran.

haniyehmortazavi.kums.ac@gmail.com

**Citation:** Seyedeh Haniyeh Mortazavi (2026). Cerebral Arterial Variants and the Neurogenesis–Angiogenesis Axis: Implications for Intraoperative Neurophysiological Monitoring. A Narrative Review and Conceptual Synthesis *Eco Science Journal*.2026 3(5).



**Copyrights** ©: This article is licensed under the Creative Commons Attribution-NonCommercial-4.0-International-License-(CCBY-NC).

**INTRODUCTION:**

Anatomical variation in the cerebral arterial supply is common rather than exceptional. Variants such as an accessory or duplicated anterior cerebral artery, a fetal-type posterior cerebral artery, or persistence of embryonic carotid-vertebrobasilar anastomoses are encountered routinely on diagnostic angiography and during neurosurgical and endovascular procedures<sup>[1-7]</sup>. These variants are not incidental curiosities: they reshape the territory at risk during temporary or permanent vessel occlusion, alter the efficiency of collateral recruitment, and can therefore change the clinical consequences of an otherwise identical surgical maneuver performed in two different patients<sup>[1,3,5]</sup>.

A separate, well-developed line of research has shown that angiogenesis and neurogenesis are not independent processes but are mechanistically coupled within a shared 'neurovascular niche,' both during development and after injuries such as ischemic stroke<sup>[8-10]</sup>. Endothelial cells and remodeling microvasculature provide trophic and migratory cues for neural progenitors, and this coupling appears to influence the brain's capacity for structural and functional recovery<sup>[8-10]</sup>.

Intraoperative neurophysiological monitoring sits at the functional intersection of these two literatures. By tracking somatosensory, motor, auditory, and visual evoked potentials, IONM offers a real-time, indirect index of perfusion adequacy within specific vascular territories during cerebrovascular surgery<sup>[11-13]</sup>. Despite this, the IONM literature and the vascular-variant literature have developed largely in parallel, with limited cross-referencing. This review brings the two together, summarizes the relevant evidence in each domain, and proposes a conceptual framework for future research that treats vascular variant anatomy and neurovascular niche biology as factors that could refine the interpretation and design of IONM protocols.

**Anatomical Variants of the Cerebral Arterial Tree****Embryological basis**

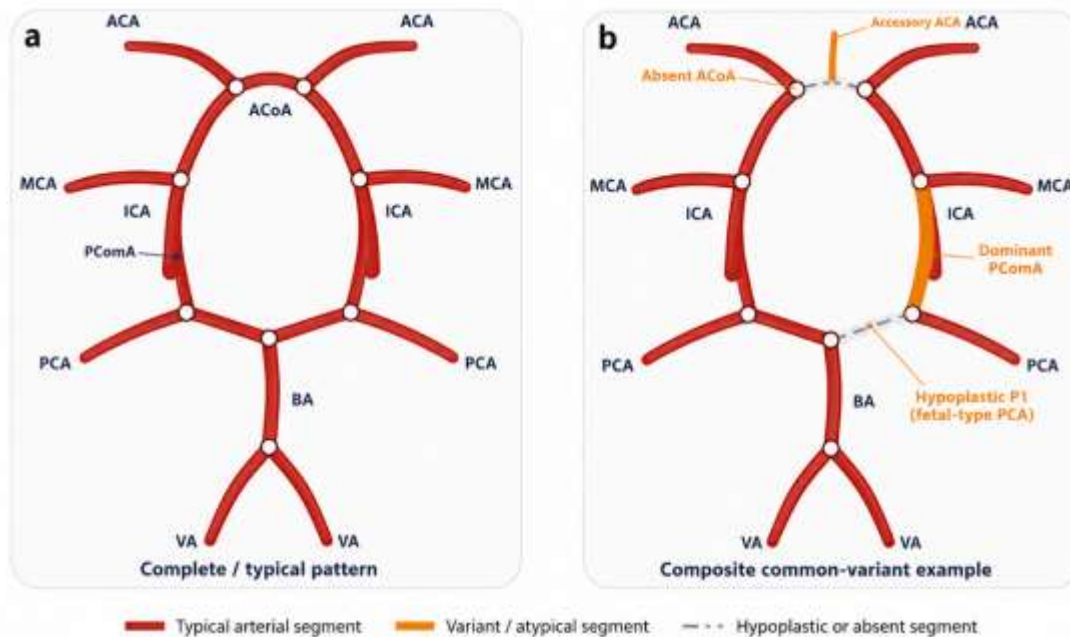
The definitive cerebral arterial pattern emerges from the regression and remodeling of a transient, redundant embryonic vascular plexus. Persistence of channels that normally regress, or premature regression of channels that normally persist, produces the variant patterns seen in adult angiography<sup>[1,6,7]</sup>. Comparative and embryological analyses indicate that this developmental logic is conserved across vertebrates, which is why recognizably similar variant patterns recur across individuals and even across species<sup>[6]</sup>.

**Anterior and posterior circulation variants**

In the anterior circulation, accessory and duplicated anterior cerebral arteries are among the more frequently reported morphological variants, with meta-analytic data drawn from tens of thousands of patients confirming their clinically relevant prevalence<sup>[4]</sup>. In the posterior circulation, the fetal-type posterior cerebral artery, in which the posterior communicating artery is the dominant supply to the posterior cerebral artery territory rather than the basilar bifurcation, is a well-described and clinically significant variant affecting collateral dynamics and aneurysm risk at the posterior communicating segment<sup>[5]</sup>. Additional embryological remnants, including persistent trigeminal or primitive olfactory arteries and carotid-vertebrobasilar anastomoses, are less common but carry specific procedural implications when encountered unexpectedly during endovascular or open surgery<sup>[2,6,7]</sup>.

### Collateral capacity and the circle of Willis

The completeness of the circle of Willis itself varies considerably between individuals, and an incomplete circle (for example, hypoplasia or absence of a communicating segment) can materially affect how well a given territory tolerates flow reduction during temporary occlusion<sup>[5]</sup>. Pictorial and classification-based reviews of these variants emphasize that recognizing them preoperatively, typically via CT or MR angiography, is central to safe planning for aneurysm clipping, bypass, and endovascular treatment<sup>[1,3]</sup>.



**FIG-1. Schematic of the circle of Willis: typical pattern (A) versus a composite example of common variants (B), including an absent anterior communicating artery, an accessory anterior cerebral artery, and a fetal-type posterior cerebral artery with a dominant posterior communicating segment and hypoplastic P1. Diagram is schematic and not anatomically exhaustive; see [1,3–5] for detailed anatomical classifications.**

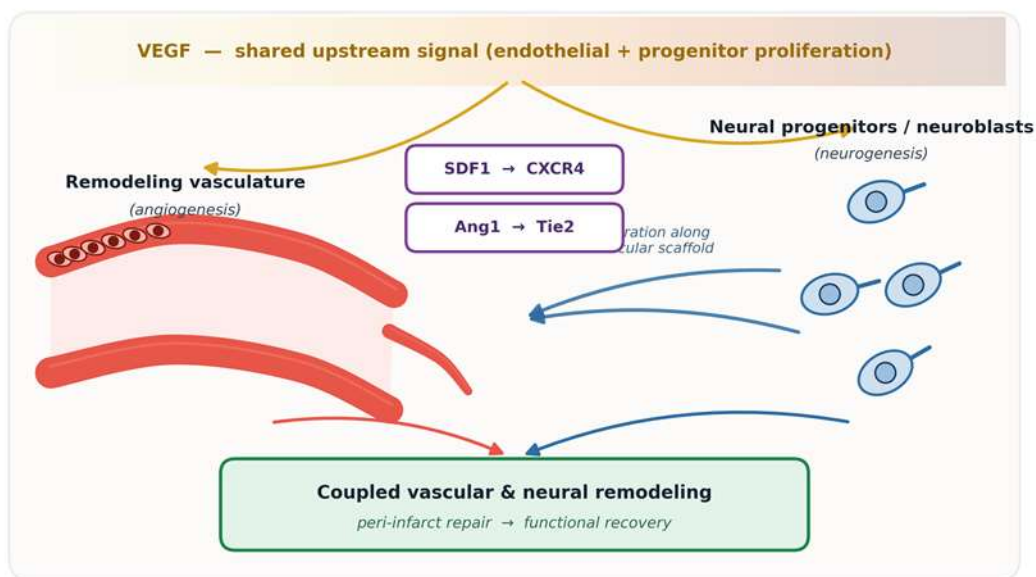
### The Neurogenesis–Angiogenesis Axis

#### The neurovascular niche

Neural progenitor cells in the adult brain's germinal zones lie in close physical proximity to remodeling capillaries, and bursts of angiogenesis coincide temporally with bursts of neurogenesis. This spatial and temporal association underlies the concept of a neurovascular niche, in which endothelial cells actively support progenitor proliferation, migration, and differentiation rather than serving merely as a passive conduit for oxygen and nutrients<sup>[8]</sup>.

#### Molecular coupling signals

Vascular-derived signaling molecules causally link the two processes. Stromal-derived factor 1 (SDF1) acting on neuroblast CXCR4 receptors, and angiopoietin-1 acting on Tie2 receptors, have been shown to guide migrating neuroblasts toward remodeling post-stroke vasculature in experimental models<sup>[8]</sup>. Vascular endothelial growth factor (VEGF) similarly promotes both endothelial proliferation and neural stem cell proliferation, positioning it as a shared upstream driver of the coupled response<sup>[9,10]</sup>.



**FIG-2. Simplified schematic of molecular coupling within the adult neurovascular niche. VEGF acts as a shared upstream signal for both endothelial and progenitor proliferation; SDF1–CXCR4 and Ang1–Tie2 signaling provide bidirectional, vasculature-guided migratory and trophic cues that couple angiogenesis and neurogenesis during post-injury repair [8–10].**

### Relevance to injury and recovery

After ischemic stroke, coordinated neurogenesis and angiogenesis in the peri-infarct region have been associated with improved functional outcomes in preclinical models, and pharmacological or cell-based strategies that augment both processes are an active area of translational research<sup>[9,10]</sup>. Coupling has also been observed in adult human tissue, supporting the relevance of these preclinical mechanisms to human cerebrovascular pathology, although direct human intraoperative correlates remain limited<sup>[9]</sup>.

### IONM as a Functional Probe of Vascular Territories

#### Modalities and vascular correlates

Different IONM modalities sample different vascular territories. Somatosensory evoked potentials (SSEPs) and motor evoked potentials (MEPs) are the primary modalities for surgery involving the internal carotid, anterior cerebral, and middle cerebral artery territories, while brainstem auditory evoked potentials (BAEPs) are used preferentially for posterior fossa procedures involving the vertebrobasilar system, and visual evoked potentials (VEPs) have an emerging but more limited role<sup>[11–13]</sup>. Electroencephalography (EEG) is additionally used to detect impending ischemia from major vessel occlusion and to titrate anesthesia during temporary clipping<sup>[11]</sup>.

Modality	Primary vascular territory	Typical surgical context
EEG	Global cortical perfusion; large-vessel (ICA/MCA) territory	Anesthesia titration during temporary clipping; large-vessel monitoring [11]
SSEP (median nerve)	MCA territory (upper-limb sensory cortex)	Anterior/middle circulation aneurysm clipping [11,13]
SSEP (tibial nerve)	ACA territory (lower-limb sensory cortex)	Anterior communicating artery / ACA aneurysm surgery [11]
MEP	ICA/ACA/MCA territory (corticospinal tract)	Aneurysm clipping, AVM resection [11,13]
BAEP	Vertebrobasilar territory (brainstem, CN VIII)	Posterior fossa, PICA, and basilar aneurysm surgery [11]
VEP	PCA / posterior circulation (visual pathways)	Posterior circulation aneurysms, occipital AVMs (emerging, limited use) [11]

ICA = internal carotid artery; ACA = anterior cerebral artery; MCA = middle cerebral artery; PCA = posterior cerebral artery; PICA = posterior inferior cerebellar artery; AVM = arteriovenous malformation.

**Table 1. IONM modalities and their corresponding vascular territories.**

**Use in aneurysm and arteriovenous malformation surgery**

IONM has become an established adjunct in aneurysm clipping and in the surgical or endovascular treatment of arteriovenous malformations, where it allows continuous assessment of the functional integrity of motor, sensory, auditory, and visual pathways during temporary or permanent vessel occlusion<sup>[11,13]</sup>. Multimodal protocols that combine SSEP, MEP, and territory-specific monitoring have been proposed specifically to match monitoring strategy to the vascular territory at risk<sup>[11]</sup>.

**Diagnostic performance and limitations**

Reported diagnostic performance for IONM in aneurysm surgery shows high specificity but variable sensitivity, reflecting the fact that small, deep, or perforator-only territories may not be adequately represented by scalp- or cortex-based recordings<sup>[11–13]</sup>. Systematic reviews of IONM in aneurysm clipping report meaningful reductions in postoperative ischemic complications associated with monitoring, while also noting substantial heterogeneity in protocols and outcome definitions across studies<sup>[12,13]</sup>.

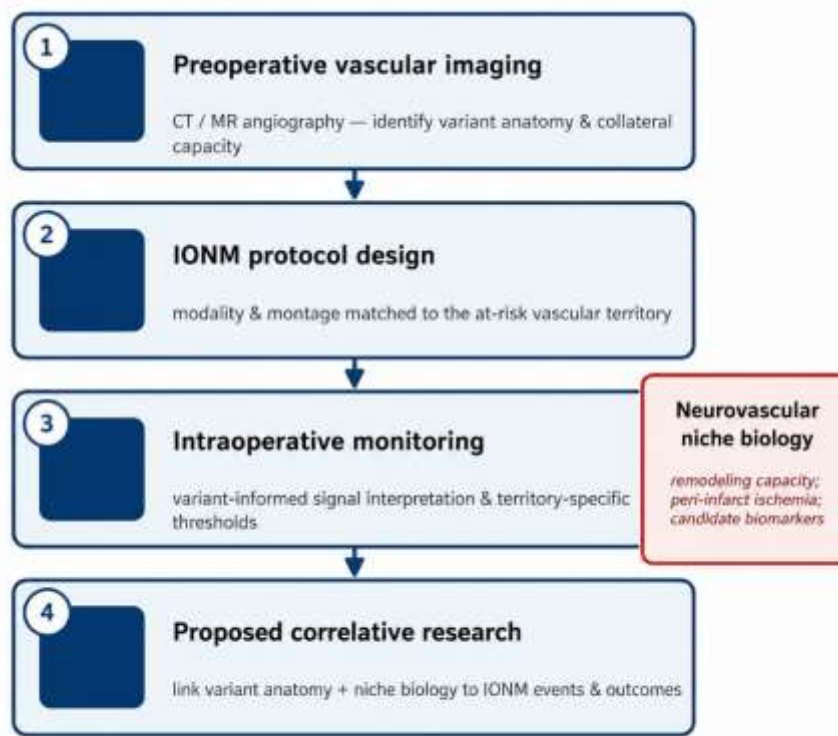
**Toward an Integrated, Variant-Aware Framework**

The two literatures reviewed above share an unexamined point of contact: both are organized around the concept of a vascular territory whose tolerance to compromised perfusion is not fixed but depends on collateral anatomy and on the local capacity for vascular and neural remodeling. We propose, as a hypothesis-generating framework rather than a demonstrated finding, that this shared organizing principle could be made explicit in three ways.

First, preoperative vascular variant mapping (CT or MR angiography) could be more systematically cross-referenced with IONM modality selection and montage design, so that monitoring is weighted toward the specific territory whose collateral support is known, from imaging, to be limited in a given patient — for example, prioritizing BAEP and brainstem-territory SSEP monitoring when a fetal-type posterior cerebral artery or an incomplete posterior communicating segment is identified preoperatively<sup>[5,11]</sup>.

Second, the threshold used to define a clinically significant intraoperative signal change might reasonably differ between patients with robust angiographic collateral capacity and those without, since the former may tolerate transient flow reduction without lasting injury while the latter may not; this remains a testable hypothesis rather than an established adjustment to current monitoring criteria<sup>[1,5,11]</sup>. Third, the neurogenesis–angiogenesis literature raises the question of whether a patient's underlying capacity for vascular and neural remodeling — for instance, inferred from a history of clinically silent prior ischemia, or in the future from candidate molecular biomarkers — could help explain otherwise unexplained variability in outcome among patients with similar intraoperative signal changes. At present this connection is mechanistically plausible based on preclinical coupling data<sup>[8–10]</sup> but has not, to our knowledge, been directly tested using human intraoperative neurophysiological data, and we present it here explicitly as a direction for future correlative research rather than a validated clinical tool.

Concretely, we suggest that retrospective cohort studies cross-referencing documented vascular variant anatomy with IONM event rates and postoperative outcomes, and prospective studies incorporating collateral-flow imaging alongside multimodal IONM, would be reasonable first steps toward testing this framework.



Status: conceptual / hypothesis-generating framework — intended to motivate future correlative and prospective studies, not a validated clinical protocol or a report of new clinical findings.

**FIG-3. Proposed conceptual framework linking preoperative vascular variant mapping, IONM protocol design, and neurovascular niche biology, intended to guide future correlative and prospective research rather than to specify a validated clinical protocol.**

### Limitations and Future Directions

This synthesis has several limitations inherent to a narrative review. The neurogenesis–angiogenesis coupling literature is drawn predominantly from rodent stroke models, and extrapolation to the intraoperative human setting, where the relevant time frame is minutes to hours rather than days to weeks, is speculative. The vascular-variant and IONM literatures were each reviewed selectively rather than systematically, and publication and reporting heterogeneity across IONM studies limits direct comparison of sensitivity and specificity estimates<sup>[11–13]</sup>. No new patient data, imaging, or monitoring records are presented; the integrative framework in Section 5 is explicitly hypothesis-generating and requires prospective validation before any change to clinical monitoring practice could be justified.

**CONCLUSION:** Cerebral arterial variants and the neurogenesis–angiogenesis axis have largely been studied as separate problems, yet both converge on the same underlying question: how much functional reserve does a given vascular territory have, and how is that reserve best tracked in real time during surgery. Intraoperative neurophysiological monitoring is, in principle, well positioned to serve as that real-time readout. Bringing vascular variant anatomy and neurovascular niche biology explicitly into the design and interpretation of IONM protocols is a plausible and testable direction for future research, with the long-term goal of more individualized, mechanistically informed intraoperative monitoring.

### BIBLIOGRAPHY:

1. Okahara M, Kiyosue H, Mori H, Tanoue S, Sainou M, Nagatomi H. Anatomic variations of the cerebral arteries and their embryology: a pictorial review. *Eur Radiol.* 2002;12(10):2548–2561. doi:10.1007/s00330-001-1286-x
2. Uchino A. Carotid-vertebrobasilar anastomosis: magnetic resonance and computed tomographic angiographic demonstration. *Jpn J Radiol.* 2019;37(8):565–578. doi:10.1007/s11604-019-00847-x
3. Hakim A, Gralla J, Rozeik C, Mordasini P, Leidolt L, Piechowiak E, et al. Anomalies and normal variants of the cerebral arterial supply: a comprehensive pictorial review with a proposed workflow for classification and significance. *J Neuroimaging.* 2018;28(1):14–35. doi:10.1111/jon.12475
4. Triantafyllou G, Paschopoulos I, Kamoutsis K, Papadopoulos-Manolarakis P, Valenzuela-Fuenzalida JJ, Sanchis-Gimeno J, et al. Morphological variations of the anterior cerebral artery: a systematic review with meta-analysis of 85,316 patients. *Diagnostics (Basel).* 2025;15(15):1893. doi:10.3390/diagnostics15151893
5. Xalxo N, Ratanpara L, Patil KS, Chauhan PR, Mehra S. Morphology and variations of the posterior cerebral artery: a literature review. *Cureus.* 2025;17(3):e81205. doi:10.7759/cureus.81205
6. Ota T. Functional arterial anatomy of the brain. *Stroke Vasc Interv Neurol.* 2022;2(5):e000446. doi:10.1161/SVIN.122.000446
7. Bertulli L, Robert T. Embryological development of the human cranio-facial arterial system: a pictorial review. *Surg Radiol Anat.* 2021;43(6):961–973. doi:10.1007/s00276-021-02684-y
8. Ohab JJ, Fleming S, Blesch A, Carmichael ST. A neurovascular niche for neurogenesis after stroke. *J Neurosci.* 2006;26(50):13007–13016. doi:10.1523/JNEUROSCI.4323-06.2006
9. Xiong Y, Mahmood A, Chopp M. Angiogenesis, neurogenesis and brain recovery of function following injury. *Curr Opin Investig Drugs.* 2010;11(3):298–308. PMID: 20178040
10. Ruan L, Wang B, ZhuGe Q, Jin K. Coupling of neurogenesis and angiogenesis after ischemic stroke. *Brain Res.* 2015;1623:166–173. doi:10.1016/j.brainres.2015.02.042

11. Staarmann B, O'Neal K, Magner M, Zuccarello M. Sensitivity and specificity of intraoperative neuromonitoring for identifying safety and duration of temporary aneurysm clipping based on vascular territory, a multimodal strategy. *World Neurosurg.* 2017;100:522–530. doi:10.1016/j.wneu.2017.01.009
12. Park D, Kim BH, Lee SE, Jeong E, Cho K, Park JK, et al. Usefulness of intraoperative neurophysiological monitoring during the clipping of unruptured intracranial aneurysm: diagnostic efficacy and detailed protocol. *Front Surg.* 2021;8:631053. doi:10.3389/fsurg.2021.631053
13. Nasi D, Meletti S, Tramontano V, Pavesi G. Intraoperative neurophysiological monitoring in aneurysm clipping: does it make a difference? A systematic review and meta-analysis. *Clin Neurol Neurosurg.* 2020;196:105954. doi:10.1016/j.clineuro.2020.105954

